DENTAL
INNOVATOR

DENTSPLY
SANKIN

CLEAR BRACKET SL+
CLEAR SNAP

Product Catalog



Precision and function

Bracket body



The twin slot body adopting a special transparent "adhesive" composite enables single-sided ligation as well as presenting esthetics. Moreover, it is free from abrasion of antagonistic teeth during treatment or micro cracks in the enamel when debonding.

Base surface

A mechanical base is adopted as the base which is a contact surface with the tooth surface, which can cope with various kinds of bonding agents, preventing the bracket from falling off. A representative light-cured type bonding agent showed average adhesive strength of 3.3 kgf. (In-house comparison)

Slot section

The slot section machined with accuracy of 1/100mm or less and using a metal plate of a patented special press bending structure to suppress frictional resistance with a wire is designed to prevent distortion of the bracket or opening of the slot due to the torque of the wire for securely transmitting specified torque to the teeth.

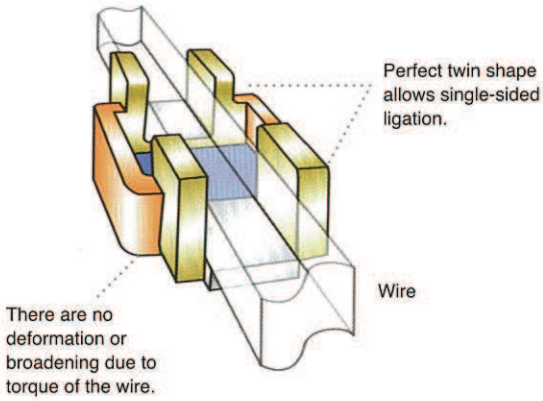

Esthetics

Gold slot

A gold slot with high flexural strength is adopted to the high transparent bracket body. Seen from the Munsell color chart which is a common color specification method, gold shows high reflectivity against a warm color light and looks bright in visible light. Making full use of characteristics of this color, the transparent bracket of the gold slot hardly stands out when attached to the tooth surface, offering esthetics with a high quality appearance. (A silver regular slot is also available.)

Total esthetics with gold wire

Furthermore, concomitant use of Ti-Ni alloy and stainless gold wires will make the "appearance" in the oral cavity brighter, suppressing the orthodontic appliance from standing out as a whole.

Clear Bracket SL + Gold Slot attached with Ti-Ni alloy peach gold wire.

Clear Bracket SL + Gold Slot attached with Ti-Ni alloy lemon gold wire.

CLEAR SNAP

The Clear Snap is a ligation appliance developed under the concept of "allowing low friction treatment without exchanging a Clear Bracket". Using a high stain-resistant polyacetal material, low friction was realized. It can be used in either size of 0.018 or 0.022 and easily attached.

Performance and function

Self ligation
Super light force system

Attaching to Clear Bracket SL+ generally litigated to be used by one-touch allows self ligation. It is not necessary to prepare the bracket "dedicated for self ligation" separately. Since common ligation can be conducted without exchanging brackets only if the Clear Snap is removed, common ligation and self ligation can be conducted with the same bracket at a necessary treatment stage. Thus, it is an economical system placing a minimal economic burden on patients.



Esthetics

Clear Snap is an appliance for self ligation developed especially for Clear Bracket SL+. Its round shape completely fits with the tiwing and the twin slot, free from unpleasant sensation when wearing the Clear Snap.

Appearance when wearing Clear Bracket SL+ attached with Clear Snap and Ti-Ni alloy peach gold wire

Easy manipulation

It can be attached to the Clear Bracket SL+ by one-touch from the cervical side. When removing, its vertical bar is cut with a pin cutter. Since there is no excessive space even wearing the Clear Snap, neither dental plaque nor the tophus collects excessively, resulting in easy oral health management.

Attachment and detachment method of a Clear Snap

Attachment

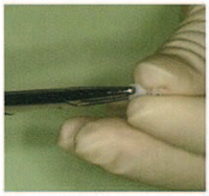

Hold the Clear Snap with pliers etc.

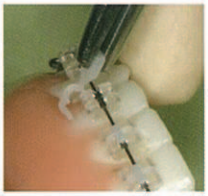

Hang on the wing on the cervical side.

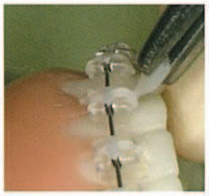

Hang on the wing on the incisal side pushing against the tooth surface.

Turn and remove the home base.

Detachment

Cut the vertical bar on the slot. Be careful not to apply such excessive force as to open the slot. Cutting while absorbing with vacuum, the Clear Snap cut can be collected easily.

With a cutter.

With a pin cutter.

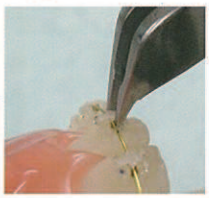

With a Clear Snap Cutter.

Clear Button

Clear Button is a special bracket which can improve without using an open coil in half crown crowded teeth to which the bracket cannot be attached.

Appearance when wearing Clear Button to the maxilla

Clear Bracket used for class II occlusion case

Kanomi Orthodontic & Pedodontal Clinic
Dentist Ryuzo Kanomi
Dentist Kimitaka Nakagawa

Dr. Ryuzo Kanomi

Dr. Kimitaka Nakagawa

First I encountered orthodontic products of Dentsply-Sankin about when I became a practitioner, and I have been using them regularly for 27 years or more since then. Moreover, from the development phase of Clear Bracket to nowadays, I have participated and cooperated in development of various products such as Clear Snap and Clear Button and conducted clinical verification from various aspects. Now, I will introduce Class II malocclusion treatment case using Clear Bracket SL+.

Although treatment will become quite easy if the treatment of Class II malocclusion is helped by growth of the mandible, it becomes the most difficult work to predict or control growth of the mandible for an orthodontist. However, it is a current situation that an experienced orthodontist performs treatment while predicting growth of a patient. I usually diagnose using two cephalometric radiographs of different periods (dental stages) as much as possible. In this case, I made diagnosis and treatment plan in consideration of direction and amount of growth using data when the patient was 10 years old.

Current symptoms

The patient was 12 years and nine months old at the start of the orthodontic treatment.

Oral findings: Maxillary protrusion accompanied by lower labioversion of the upper cuspids and high arched palate with overjet of 6.0mm and overbite of 4.0mm were observed. Moreover, dental age III C, bilateral Angle Class II molar relationship, bilateral Class II canine relationship, unerupted upper right second molar were observed, however, upper left second molar and bilateral lower second molars had started eruption, and crowding was observed in the upper and lower anterior-teeth part.

Findings in panoramic radiography: The upper left second molar and tooth germs of upper and lower third molars were observed.

Lateral cephalogram findings : With SNA of 82.5 degrees, SNB of 78.5 degrees and ANB of 4.0 degrees, the maxillomandibular relation was mild Skeletal Class II. Moreover, U1 to NA was 30.0 degrees and LI to NB was 32.0 degrees, indicating upper and lower anterior teeth labioclination.

First visit

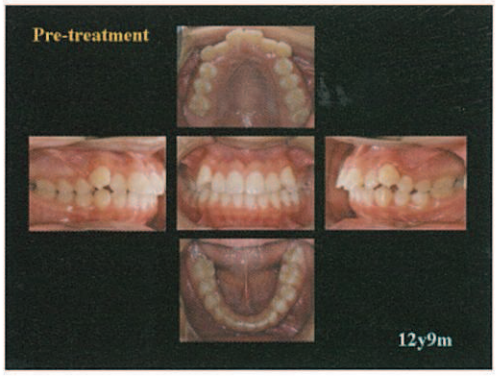



Diagnosis and treatment policy

Diagnosed as Skeletal Class II, Angle Class II div.1 accompanied by the lower labioversion of the upper cuspids. It was determined to conduct orthodontic treatment by extracting bilateral upper first premolars and bilateral lower second premolars after maxilla dilation by R.P.E to improve crowding, labioclination of upper and lower anterior teeth and Class II molar relationship.

Treatment progress

After maxillary dilation by R.P.E., for bracket, attaching a straight edgewise appliance through the 018"x025" slot of Clear Bracket SL+ gold slot, orthodontic treatment was performed according to the common step. The bilateral upper first premolars and the bilateral lower second premolars were extracted after leveling. Then, the upper and lower dentition was aligned, using a J-hookhead gear and class II rubber. The dynamic treatment period was two years and ten months.

Therapeutic result

I At the end of dynamic treatment

Oral findings: The molar relationship and the canine relationship became Angle Class I and proper overjet, overbite and good occlusal relationship were obtained.

Findings in panoramic radiography: Although slight mesial inclination was observed in the bilateral lower first molars, root parallelism became nearly good.

Findings in lateral cephalography: SNA changed from 82.5 degrees to 82.0 degrees, SNB changed from 78.5 degrees to 79.0 degrees, and ANB changed from 4.0 to 3.0 degrees and the upper and lower jaw relation was improved a little. Moreover, U1 to NA changed from 30.0 degrees to 28.5 degrees, and L1 to NB changed from 32.0 to 21.0 degrees, and the labioclination of the upper and lower anterior teeth was also improved.

At the end

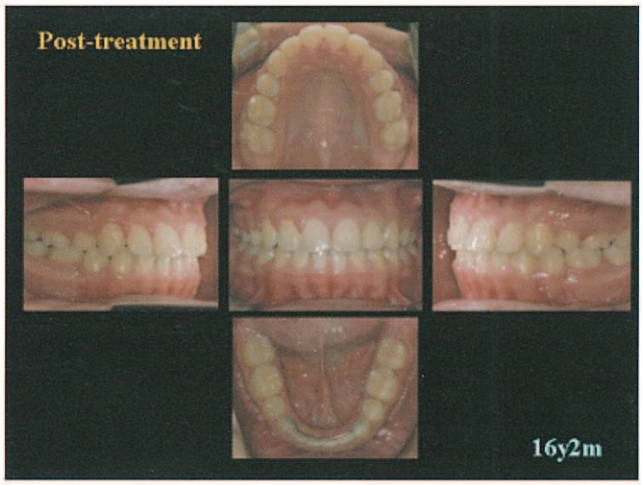

II Two years and six months after dynamic treatment

For retention, wire fixation was performed between canine teeth of the maxilla and mandible and the plate type retainer in the maxilla.

Oral findings: Upper and lower dentition was stable, and close occlusion was maintained.

Findings in panoramic radiography: Eruption of the bilateral upper and lower third molars was observed.

Findings in lateral cephalography: ANB changed from 3.0 degrees to 1.5 degrees, in connection with that, U1 to NA changed from 28.5 degrees to 32.0 degrees, and labioclination of the upper anterior teeth was observed.

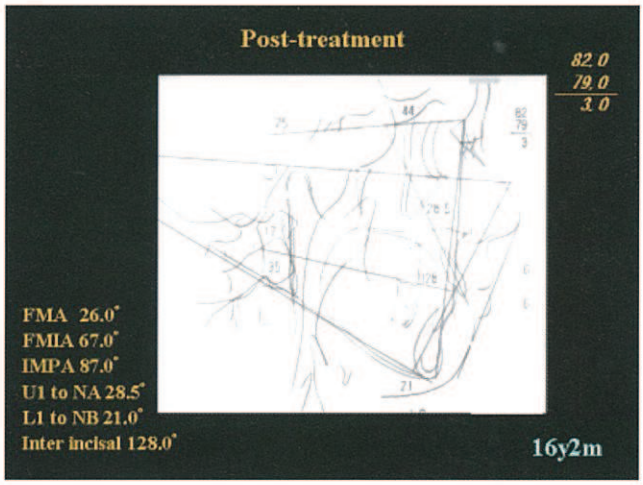

Discussion

Many cases of maxillary protraction accompanied by habit, some of them express distinct morphological change of dentition or occlusion and others express through treatment like this case. In such a case, although myofunctional therapy is needed in the middle of the treatment, lack of consciousness of the patient may lead to poor motivation and little cooperation. Since this patient continued lower lip biting habits until after end of treatment and retention, U1 to NA showed slight labioclination.

One of the major reason why I use Clear Bracket is high rigidity and smoothness of the slot part. The bracket is not deformed even with a wire of large torque, and the torque is properly applied and sliding is good.



Pain reduction effect during orthodontic treatmentwith Low friction & Low force system using Clear Snap

Masaru Yamaguchi, Kazutaka Kasai
Departments of Orthodontics, Nihon University School of Dentistry at Matsudo

Associate Professor Masaru Yamaguchi

Low friction & Low force becomes available by combining Clear Bracket, Clear Snap, and a superelasticity wire. Low friction & Low force system features that it poses little load to periodontium, leading to smooth dental movement so that pain of orthodontic treatment is relieved. However, evidence for that has not been obtained.

For pain mechanism during orthodontic treatment, if mechanical stimulation generated with a wire etc. reaches certain strength or higher, the periodontium will react to produce pain producing substances (substance P, bradykinin, serotonin, histamine, etc.) and pain enhancing substances (prostaglandin etc.) to stimulate the pain nerve ending, causing pain. The pain reduction effect of the Low friction & Low force system was investigated by comparing the yield of the substance P which is one of the pain producing substances in the gingival crevice fluid of patients under orthodontic treatment with the conventional system.

(Fig.1) Substance P measurement site

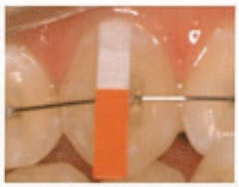

Subjects and method

In patients under treatment at the Departments of Orthodontics, Nihon University School of Dentistry at Matsudo, yield of the substance P in the gingival crevice fluid during leveling with the Low friction & Low force system (Dentsply-Sankin) (right) and conventional ligation (left) was investigated. (Fig.1, 2)

(Fig.2) Clear Snap and common litigation

Clear Snap ◂ ▸ Conventional ligature wire

Results

Although the yield of the substance P in the gingival crevice fluid between 0 to 168 hours after wearing wires reached maximum at 24 hours in both Low friction & Low force system and conventional ligation groups, it was suppressed to about half with the Low friction & Low force system (right-hand side) compared with conventional ligation (left). (Fig.3)

The yield of the substance P in the gingival crevice fluid in 24 hours after wearing wires from the medial incisor and the first molar was suppressed to about half with the Low friction & Low force system (right-hand side) compared with conventional ligation (left) (Fig.4).

(Fig.3)

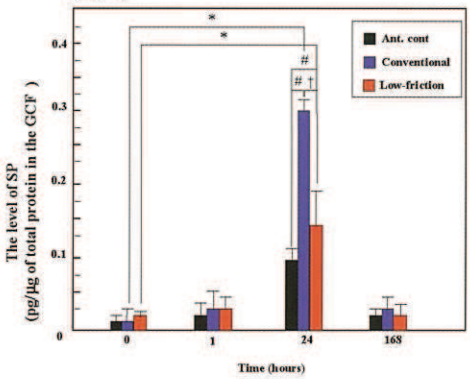

(Fig.4)

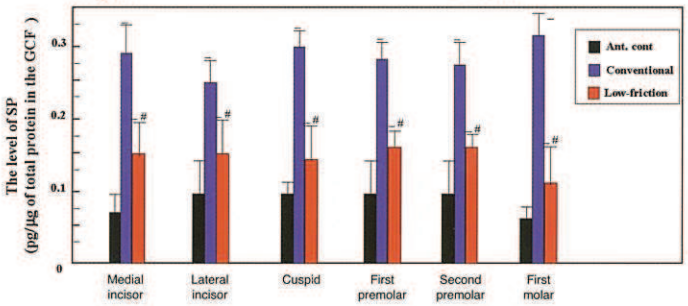

Conclusion

It was suggested that the Low friction & Low force system reduces pain during orthodontic treatment compared with the conventional system.